

# Change in trend of hollow viscus perforation: a retrospective study

**B. A. Kolhar, Y. P. Lamani, B. V. Goudar, E. B. Kalburgi, B. K. Bhavi, Mohammedgouse Karikazi, Mahantayya Ganjigatti, Suhas B S.**

Department of General Surgery, S. Nijalingapa Medical College and Hangal Shri Kumareshwar Hospital, Bagalkot, Karnataka, India.

## Abstract

**Background:** India is a developing country and there has been a considerable change in management of infectious disease leading to decline in the complications; despite which gastrointestinal perforations constitute to be most common surgical emergencies. Our objective was to determine the change in the trend of proximal versus distal perforation and the decline in infectious aetiology.

**Methods:** Retrospective study of 85 consecutive patients from January 2013 to December 2015 were reviewed with respect to presentation, intraoperative findings and post operative course at our tertiary care hospital in district of Bagalkot, North Karnataka.

**Results:** The most common cause of perforation in our study was perforated duodenal ulcer (44 cases) followed by appendicitis (20 cases), gastrointestinal perforation due to blunt trauma abdomen (7 cases), penetrating abdominal injury (1 case), typhoid fever (3 cases) and tuberculosis (2 cases). Overall mortality was 2.35 %.

**Conclusion:** As in developed countries there is decrease in incidence of proximal versus distal perforations in India, today. This is due to improvement in the medical management of infectious disease. The increasing incidence of post-traumatic gastrointestinal perforation is due to an increase in motor vehicle accidents. However, the incidence can still be reduced to a low number with the improvement in health education, early diagnosis with effective medical management of the infections and measures to prevent Road Traffic Accidents.

Key words: Hollow viscus perforation, typhoid perforation, peritonitis.

## Introduction

Perforation of any part of gastrointestinal tract gives rise to life threatening emergency. A high index of suspicion is essential to diagnose gastrointestinal perforation early as significant morbidity results from diagnostic delay. The spectrum of aetiology of perforation in tropical countries continues to be different from its western counterpart. The great majority of perforation from stomach and duodenum are complications of peptic ulcer<sup>[1]</sup>. The management of perforated viscus challenges the surgeons skill and his knowledge of preoperative and postoperative care of the severely ill surgical patients<sup>[2]</sup>.

## Material and Methods

A retrospective study of 85 patients of gastrointestinal

perforation was done over a period of last 3 years at tertiary care hospital in district of Bagalkot, North Karnataka.

All patients with acute abdomen and free gas under diaphragm; and all cases found to have perforation of any part of gastrointestinal tract at the time of surgery were included in the study.

All cases with either primary peritonitis or that due to anastomotic leak were excluded. Patients less than 14 years of age were also excluded.

All cases were studied in terms of clinical presentation, radiological investigations, operative findings and postoperative course. Data was collected from medical records department, admitted patient records, operation theatre records and outpatient department

## Address for Correspondence

**Dr. B.A. Kolhar**

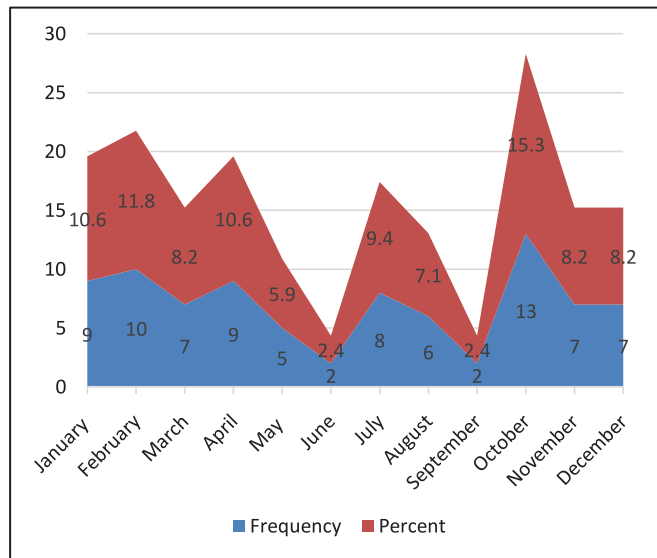
Assistant Professor Department of General Surgery, S. Nijalingapa Medical College, Bagalkot, Karnataka, India.

E-mail: drbasavarajk@gmail.com

follow up of cases. All patients following a clinical diagnosis of perforation peritonitis and adequate resuscitation underwent emergency exploratory laparotomy. After thorough examination the site of perforation was being identified and definitive procedure done accordingly. Post operatively patients were managed at surgical intensive care unit till post operative day 3 and if uneventful shifted to general wards or managed accordingly at surgical intensive care unit.

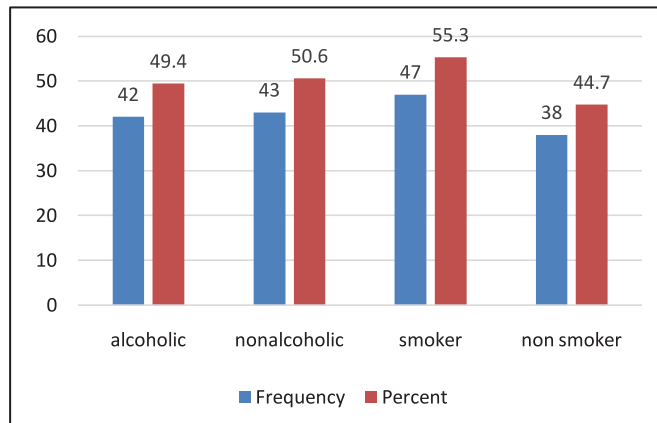
**Results**

A total of 85 patients were studied. Maximum number of cases were seen during month of October-15.3% (13) and minimum in September- 2.4% (2) (Figure 1).



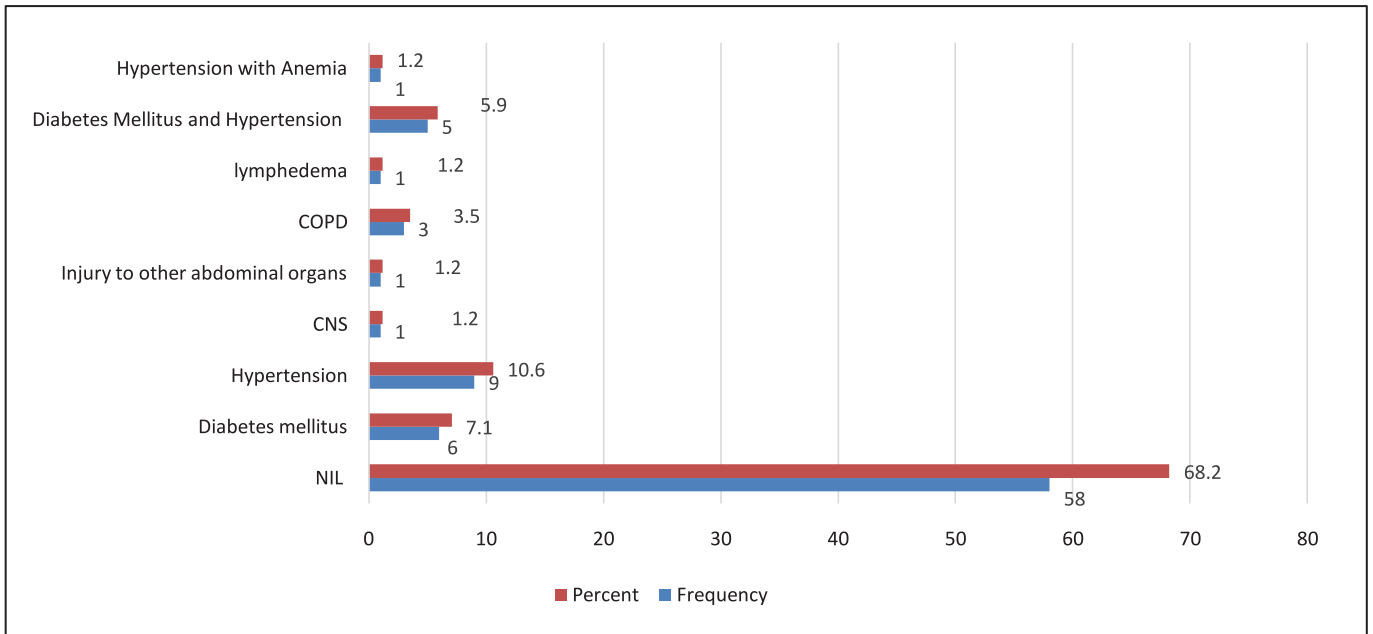
**Figure 1. Month-wise incidence of cases**

49.4 % (42) and 53.3 % (47) of patient had history of consumption of alcohol and smoking respectively (Figure 2).



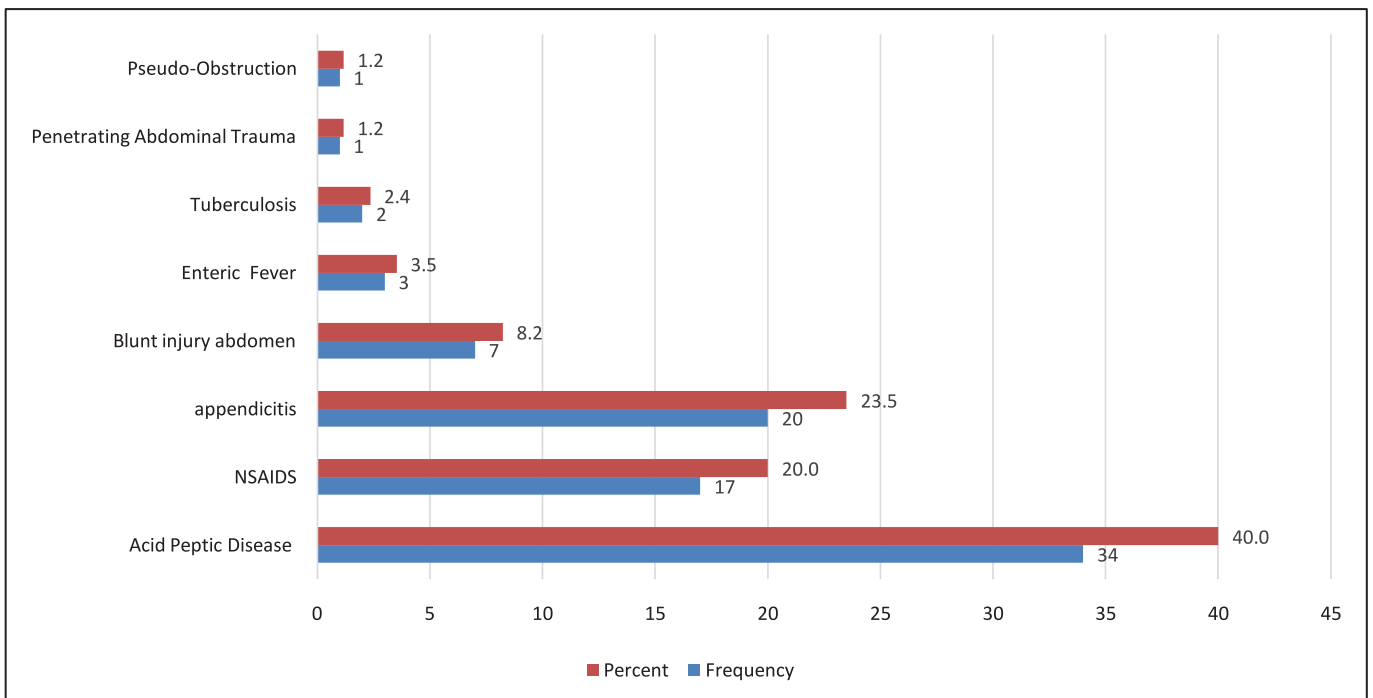
**Figure 2. Proportion of alcoholics and smokers in the cases**

31.8% of the patients had at least one pre-existing medical illness most common being Hypertension, 10.6% (Figure 3).



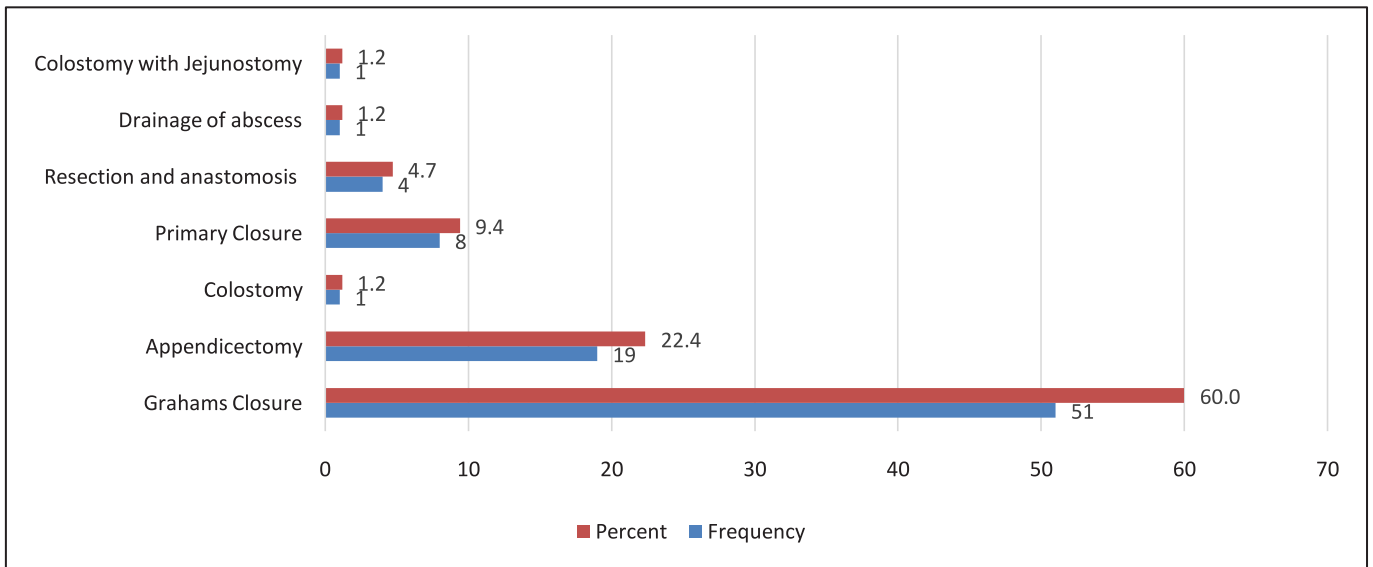
**Figure 3. Co- morbidities associated with hollow viscus perforation**

8.2% patients had perforation due to blunt injury of abdomen following road traffic accident. And 1 patient developed jejunal perforation due to stab injury. One case was secondary to pseudo-obstruction. 3.5 % patient had ileal perforation secondary to typhoid fever. 2 patients were due to tuberculosis (Figure 4).



**Figure 4. Causes for Perforation**

3 patients with duodenal perforation, 1 with colon perforation and patients with appendicular perforation (totally 23 cases, 27.06 %) did not show free gas under diaphragm .

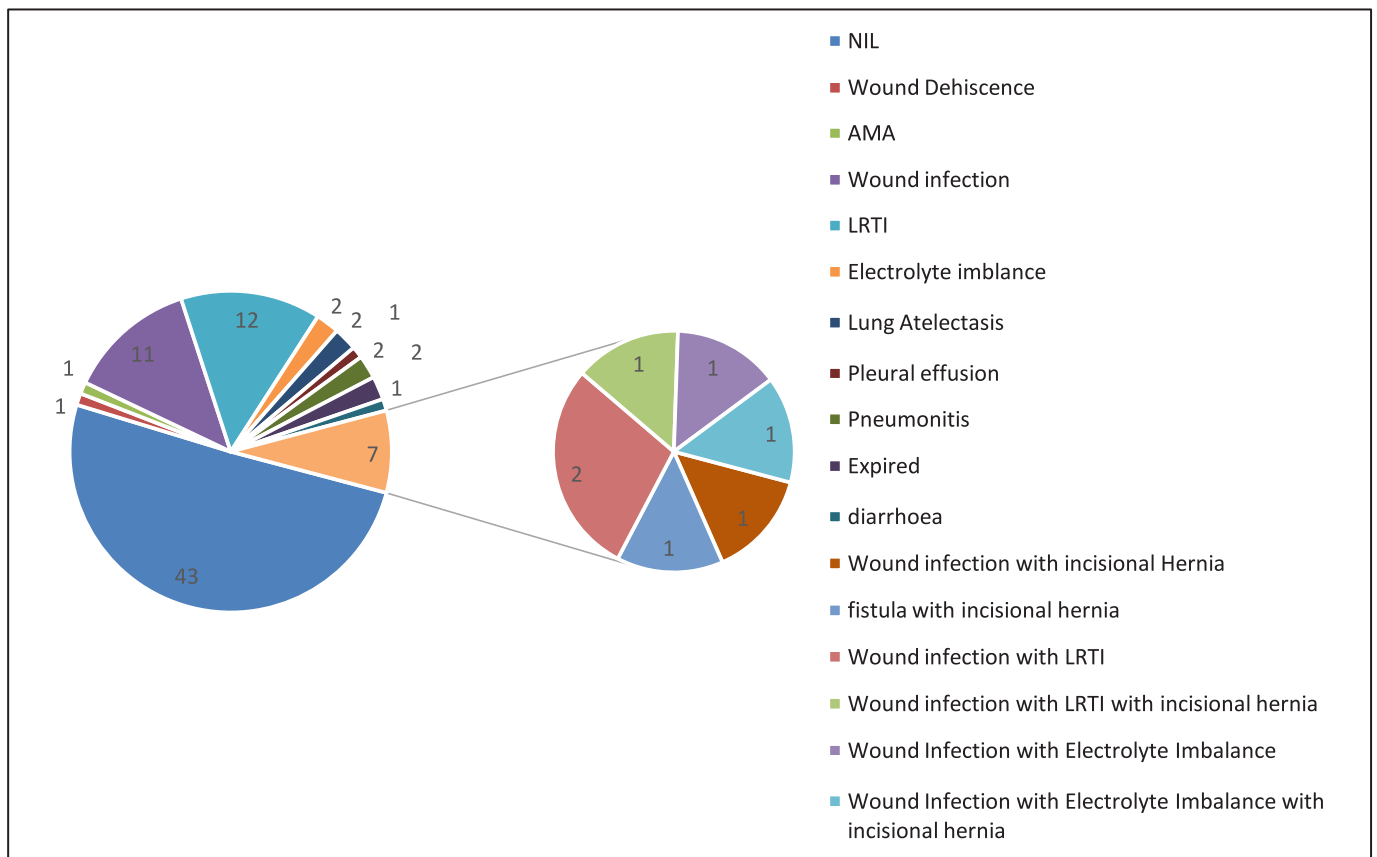


**Figure 5: Procedure Done**

In majority of patients (57) 67.1% the peritonitis was generalized. The other operative findings and surgical procedures performed are as illustrated in Figure 5. 37 cases incurred postoperative complications.

The morbidity rate in our study was significantly higher in the patients with jejunal perforation, 83% (5 out of 6 cases) and lowest in appendicular perforation, 15% (3 out of 20 cases) (Figure 6).

**Figure 6. Post-operative complications**



**Figure 6. Post-operative complications**

## Discussion

The results obtained in our study are comparable to other studies published in India. Perforation peritonitis is a frequently encountered surgical emergency in tropical countries like India, most commonly affecting

would like to suggest that there is a slight trend in increase of perforation secondary to trauma, mainly road traffic accidents and prevention of the same will lead to decrease in morbidity and mortality from distal perforation. There is also trend of decline in the

**Table 1. Review of various Studies regarding site of perforation**

Author (Ref)	Total cases	Gastroduodenal	Small Bowel	Appendicular	Colorectal	Mortality
Our Study	85	52	11	20	2	2.35%
Kemparaj T et al <sup>[3]</sup>	369	169	146	40	14	13.8%
Jhobta et al <sup>[12]</sup>	504	331	92	59	19	10.1%
Quereshi <sup>[13]</sup>	126	31	37	12	3	15%
Nishida <sup>[14]</sup>	229	92	71	0	66	13.1%
Chen <sup>[15]</sup>	98	57	6	13	14	NA
Dorairajan <sup>[16]</sup>	250	80	103	38	5	9.2%
Dandapat <sup>[17]</sup>	340	276	34	22	4	15.9%
Sharma <sup>[18]</sup>	155	47	62	23	2	8.4%
Shah <sup>[19]</sup>	110	51	16	31	3	6.4%
Kachroo <sup>[20]</sup>	90	15	13	37	2	8.8%

young men in the prime of life as compared to the studies in the west<sup>[3,4]</sup>, where the mean age is between 45–60 years. In majority of cases, the presentation to the hospital is late with well established generalized peritonitis with purulent/fecal contamination and varying degree of septicemia. The signs and symptoms are typical and it is possible to make a clinical diagnosis of peritonitis in all patients.

The perforations of proximal gastrointestinal tract, 61.18% (52) were only 1.18 times more common as perforations of distal gastrointestinal, 38.82% (33) tract compared to previous studies done in India, which show proximal being 6 times more common than distal. This suggests a decrease in trend of proximal perforation and shift of the trend from proximal to distal in India<sup>[5,6]</sup>. As data from developed countries like United States<sup>[7]</sup>, Greece<sup>[8]</sup> and Japan<sup>[9]</sup> studies suggesting distal perforation more common than proximal.

Regarding etiology of distal perforations where in previous data suggested importance of infection and infestation in India; our data is also consistent where in perforation from appendicitis, enteric fever and tuberculosis were 75.76% (25) and 3.13 times more common than that from trauma being 24.24% (8). Study from Bose et al<sup>[5]</sup> shows increased incidence of perforation due to road traffic accidents and reason was concluded being close to national highway near Chandigarh. But our hospital being not close to any national highway still there was comparable data for perforation secondary to abdominal injury. Thus, we

cause of perforation from infectious origin mainly tuberculosis and typhoid as compared to incidences from previous studies, which is depicted in detail in table 1 and table 2.

**Table 2. Review of various studies regarding infectious etiology and trauma**

Author	Total cases	Typhoid	Tuberculosis	Trauma
Our study	85	3 (3.5%)	2 (2.4%)	7 (8.2%)
Kemparaj T et al <sup>[3]</sup>	369	102 (27.64%)	10 (2.71%)	23 (6.23%)
Jhobta et al <sup>[12]</sup>	504	41(8.13%)	20 (3.97%)	45 (8.93%)

We had a mortality of 2.35% being less than other studies as shown above. This could be concluded from improvement in management (resuscitation, pre-hospital treatment, postoperative care and use of newer generation of antibiotics) of perforative peritonitis.

**Conclusion:** As is in developed countries, there is a decrease in incidence of proximal versus distal perforations in India, today. This is due to improvement in the medical management of infectious disease. The increasing incidence of post-traumatic gastrointestinal perforation is due to an increase in motor vehicle accidents. However, the incidence can still be reduced to a low number with the improvement in health education, early diagnosis with effective medical management of the infections and measures to prevent road traffic accidents.

## References

1. Taylor BA. Spontaneous perforation of the gastrointestinal tract. In: *Gastrointestinal Emergencies*. 1<sup>st</sup> edition. Gilmore Ian T, Robert Shields, editors. London: W.B. Saunders company, 1992. p.359-379.
2. Schumer W, Burman S. The perforated viscus diagnosis and treatment in surgical emergencies. *The surgical clinics of North America*. (edited by Nyhus Lloyd M) 1972;52(1):231-238.
3. Kemparaj T, Khadri S. Gastrointestinal Perforations - Our Experience. *The Internet Journal of Surgery*. 2012; 28 (2).1-6
4. Afridi SP, Malik F, Ur-Rahman S, Shamim S, Samo KA. Spectrum of perforation peritonitis in Pakistan: 300 cases Eastern experience. *World Journal of Emergency Surgery* 2008; 3:31.
5. Bose SM, Kumar A, Chaudhary A, Dhara I, Gupta NM, Khanna SK. Factors affecting mortality in small intestinal perforation. *Indian J Gastroenterol* 1986, 5(1):261-63.
6. Tripathi MD, Nagar AM, Srivastava RD, Partap VK. Peritonitis – study of factors contributing to mortality. *Indian J Surg*; 1993; 55: 342-9.
7. Washington BC, Villalba MR, Lauter CB. Cefamendole erythromycin-heparin peritoneal irrigation. An adjunct to the surgical treatment of diffuse bacterial peritonitis. *Surgery*; 1983; 94: 576-81.
8. Nomikos IN, Katsouyanni K, Papaioannou AN. Washing with or without chloremphenicol in the treatment of peritonitis. A prospective clinical trial. *Surgery* 1986; 99: 20-25.
9. Shinagawa N, Muramoto M, Sakurai S, Fukui T, Hon K, Taniguchi M, Mashita K, Mizuno A, Yura J. A bacteriological study of perforated duodenal ulcer. *Jap J Surg* 1991; 21: 17.
10. Khanna AK, Mishra MK. Typhoid perforation of the gut. *Postgraduate Medical Journal* 1984; 60: 523.
11. Noon GP, Beall AC, Jorden GL. Clinical evaluation of peritoneal irrigation with antibiotic solution. *Surgery* 1967; 67: 73.
12. Rajender S Jhobta, Ashok K Attri, Robin Kaushik, Rajeev Sharma, Anupam Jhobta. Spectrum of perforation peritonitis in India - review of 504 consecutive cases. *World Journal of Emergency Surgery* 2006; 1: 26.
13. Quereshi AM, Zafar A, Saeed K, Quddus A. Predictive power of Mannheim Peritonitis Index. *JCPSP* 2005; 15: 693-6.
14. Nishida T, Fujita N, Megawa T, Nakahara M, Nakao K. Postoperative hyperbilirubinemia after surgery for gastrointestinal perforation. *Surgery Today* 2002; 32: 679-84.
15. Chen SC, Lin FY, Hsieh YS, Chen WJ. Accuracy of ultrasonography in the diagnosis of peritonitis compared with the clinical impression of the surgeon. *Arch Surg* 2000; 135: 170-74.
16. Dorairajan LN, Gupta S, Suryanarayana Deo SV, Chumber S, Sharma LK. Peritonitis in India - A decade's experience. *Trop Gastroenterol* 1995; 16: 33-8.
17. Dandapat MC, Mukherjee LM, Mishra SB, Howlader PC. Gastrointestinal perforations. *Indian J Surg* 1991; 53: 189-93.
18. Sharma L, Gupta S, Soin AS, Sikora S, Kapoor V. Generalized peritonitis in India-the tropical spectrum. *Jpn J Surg* 1991; 21: 272-7.
19. Shah HK, Trivedi VD. Peritonitis - a study of 110 cases. *Indian Practitioner* 1988; 41: 855-60.
20. Kachroo R, Ahmed MN, Zargar HU. Peritonitis – An analysis of 90 cases. *Indian J Surg* 1984; 46: 204-9.

Conflict of interest: **Nil**

Source of funding: **Nil**

Date received: June 18th 2016

Date accepted: June 21st 2016